

# Age: More Than Just a Number? A Multimodal Characterization of APOE4

A. Koganov<sup>1</sup>, H. Stotland<sup>1</sup>, N. Cavallaro, MS<sup>1</sup>, A. Maheswari<sup>1</sup>, T. Chukwemenka<sup>1</sup>, N. Sundaraj<sup>1</sup>, S. D'Argenio<sup>1</sup>, D. Weiss<sup>1</sup>, G. Botelho<sup>1</sup>, R. Ahuja<sup>1</sup>, A. Wu<sup>1</sup>, R. Blake<sup>1</sup>, C. Kappel<sup>1</sup>, P.P. Kulkarni, PhD<sup>1</sup>, C.F. Ferris, PhD<sup>1,2</sup>

<sup>1</sup>Center for Translational Neuroimaging, Northeastern University, Boston, MA USA; <sup>2</sup>Pharmaceutical Sciences, Northeastern University, Boston, MA USA

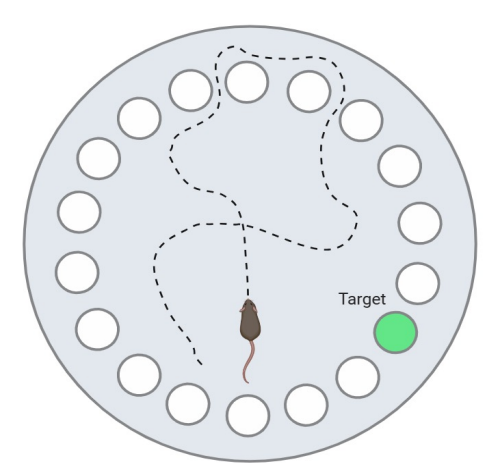
## Background & Goals

Apolipoprotein E (APOE), a lipid and cholesterol transport protein in the brain, has largely been associated with the development of Alzheimer's disease. Homozygous presentation of the APOE4 allele has been shown to significantly increase the likelihood of developing late-onset disease symptoms such as memory loss, cognitive decline, and disorientation. The goal of this study was to utilize behavioral and MRI techniques to assess the impacts of homozygous APOE4 inheritance on cognitive and motor function, as well as brain microstructure. The study aimed to validate the APOE4 model for Alzheimer's research and provide insights on the allele's underlying mechanisms.

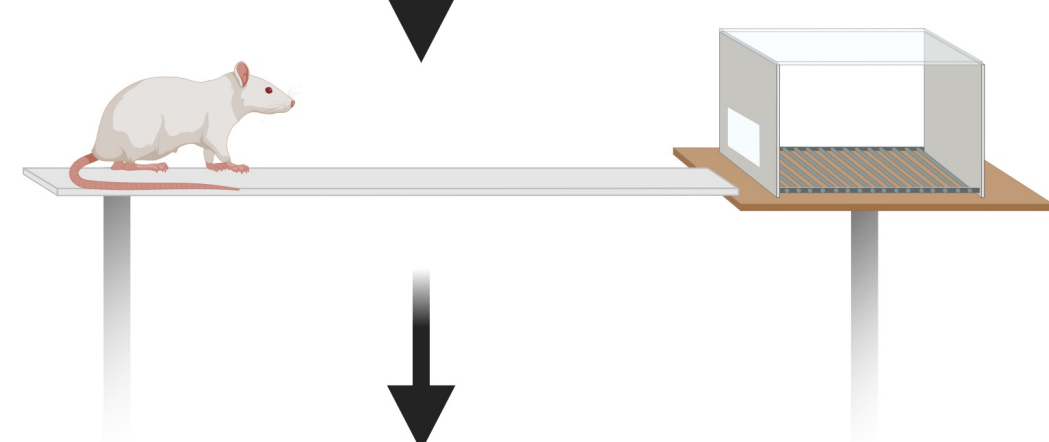
## Process and Methods

Female APOE4 (n=27) and neutral allele APOE3 (n=6) rats were split into 6 cohorts and then subjected to four different behavioral assays: the Barnes Maze to examine spatial memory, the Balance Beam to measure motor function, the Open Field Test to examine anxiety-related behavior, and Novel Object Recognition to assess recognition memory. Upon completion of behavioral testing, T2 Weighted Anatomy and Diffusion Tensor Imaging (DTI) were performed to assess region-dependent brain volume and directionality of water diffusion, respectively. All imaging was conducted while subjects were under anesthesia, and all experiments were conducted under reverse L/D cycles to preserve circadian rhythms.

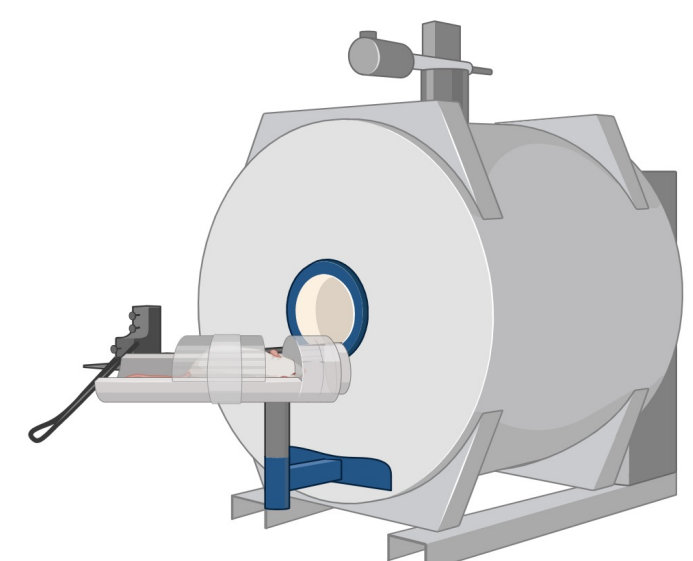
Barnes Maze (days)  
Day 1: Habituation  
Day 2-5: Memory Testing



Balance Beam (3 days)  
Day 1, 2: Training  
Day 3: Motor testing



MRI Scans: VBM, DTI



## Significant Findings

### Behavior

- APOE4 rats took greater amounts of time to find target hole in Barnes Maze and made more errors in comparison to APOE3 counterparts.
- Time and number of errors decreased at similar rates in both groups
- APOE3 rats had higher number of foot slips on Balance Beam
- Novel Object Recognition (NOR) and Open Field Test (OFT) data were also collected but did not show significance

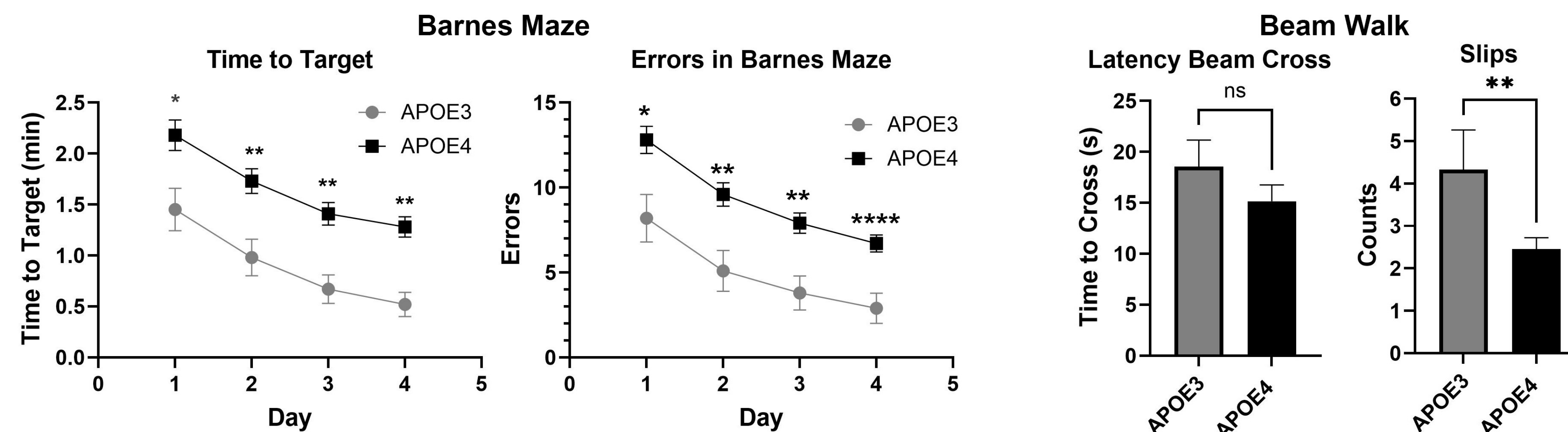
### Voxel-Based Morphometry

- APOE4 rats had higher whole brain volume than APOE3 counterparts, with the greatest changes found in the sensorimotor cortex, olfactory system, basal ganglia, and hippocampus

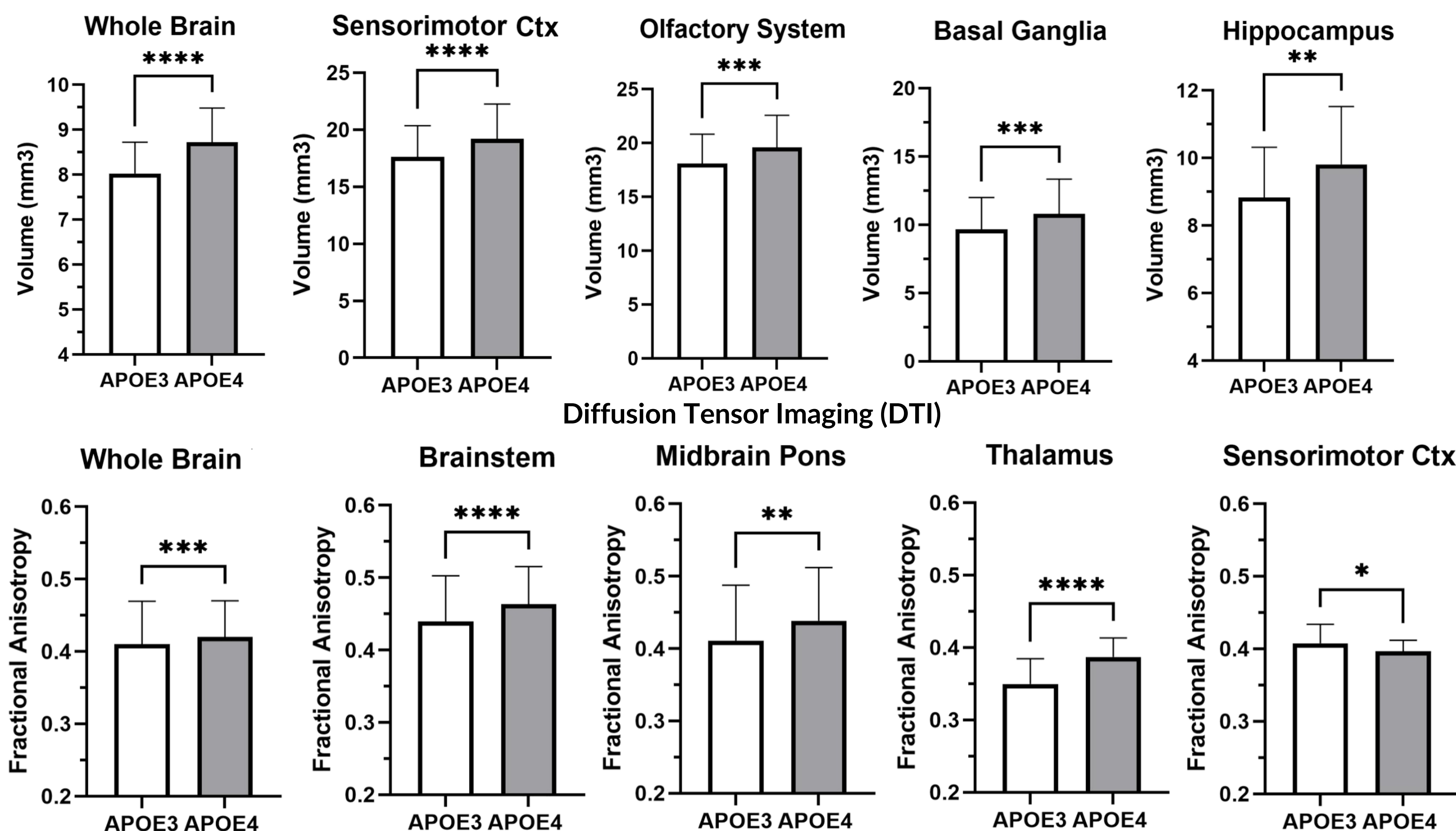
### Diffusion Tensor Imaging

- APOE4 rats had greater whole brain fractional anisotropy (FA), with most significant differences found in the brain stem, thalamus, midbrain pons, and sensorimotor cortex

### Behavioral Data



### Voxel-Based Morphometry (VBM)



## Conclusion

This study showed that while homozygous APOE4 rats experienced some deficits in memory in comparison to their APOE3 counterparts, the rate of improvement was almost equivalent, suggesting that their learning capacity is unchanged. The balance beam results suggest that APOE4 inheritance does not harm sensorimotor capabilities. It should be of note that while statistical significance was not measured for the mass of each rat, the APOE4 animals had larger masses on average, providing possible reasoning for the larger whole brain volumes. Astrogliosis, or the increase in proliferation and inflammation of astrocytes, is a common finding in Alzheimer's models, and may also contribute to these findings, as increases in astrocyte number and density could explain the tissue volumes found in the VBM analysis. The larger fractional anisotropy values in the APOE4 model suggests more directional and ordered diffusion of water in the brain, which can correlate with greater white matter integrity. Due to the neurodegenerative nature of the APOE4 allele, further exploration of white matter tracts is necessary to diagnose these findings.

## Future Directions

### Symptom Treatment:

- Explore use of psychedelic drugs, lipid biomarkers to try and reverse memory deficits

### Assessment of White Matter

- Utilize novel atlas system to properly analyze white matter integrity

### Sex-Dependent Effects

- Explore phenotypical differences in memory and brain microstructure between males and females

### Histological Analysis

- Extract tissue samples (brain, heart, liver, kidney, etc.) to assess damage and inflammation

## Acknowledgements



Northeastern University  
Center for Translational Neuro-imaging